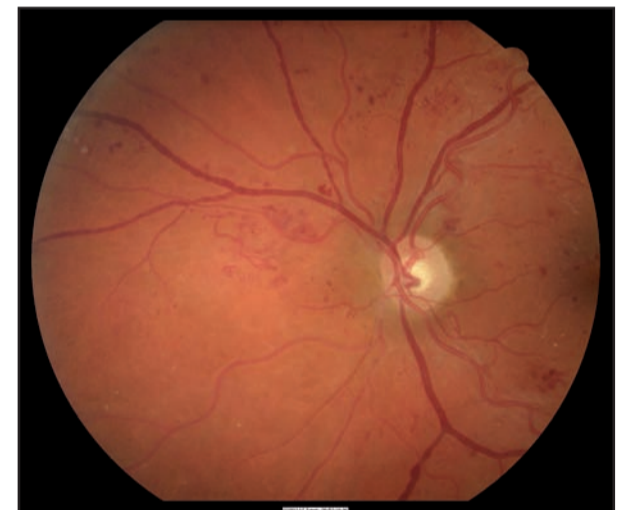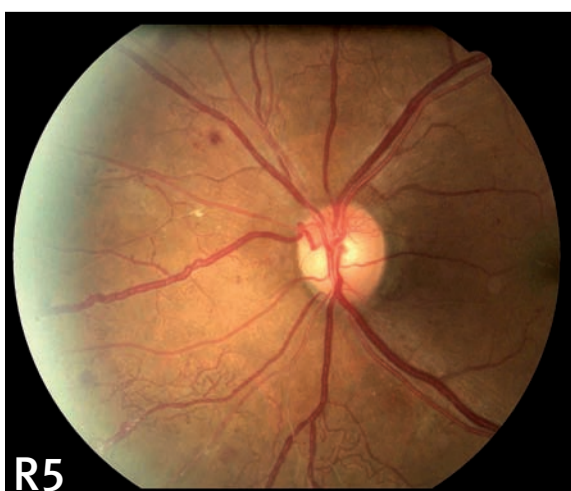
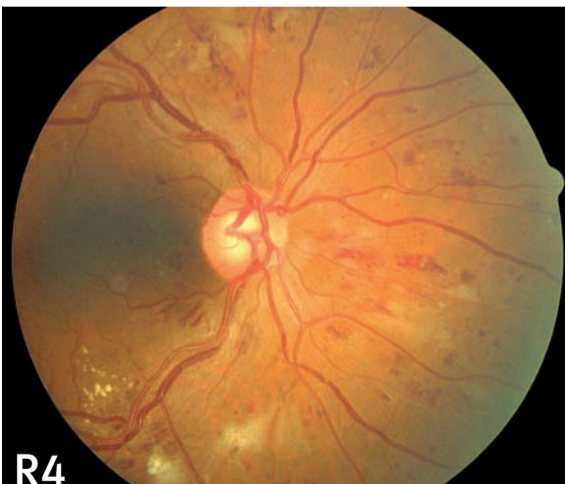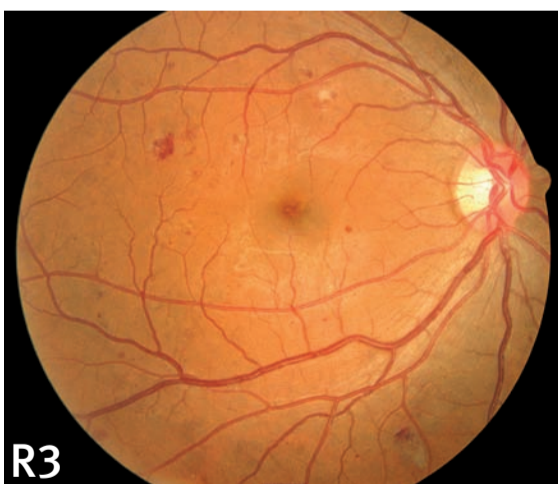
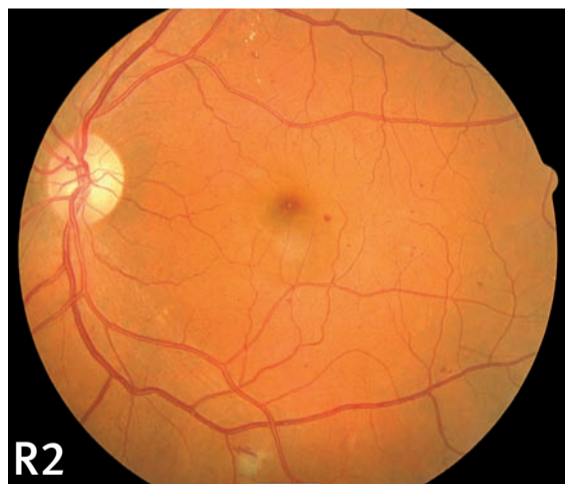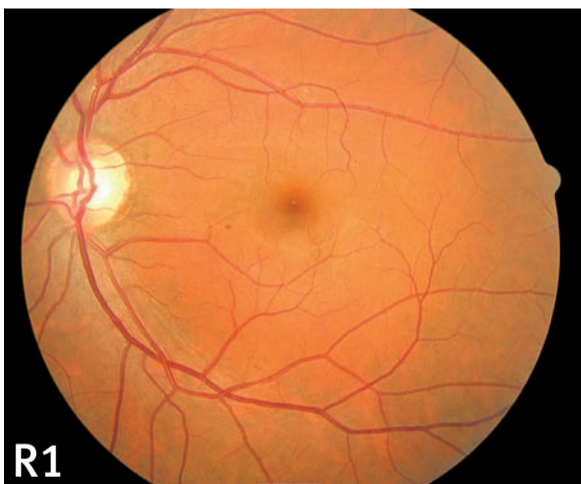


National Diabetes Retinal Screening Grading System and Referral Guidelines 2006

Chart 1: Diabetic Retinopathy (Retina Peripheral To Macula)

Retinopathy Grade	Clinical Signs	Outcome	Minimum Level of Grader (DHB Designated Ophthalmologist approved)
R0/M0 No retinopathy	No abnormalities.	Biennial Photoscreen.	Primary grader
R1 Minimal	< 5 microaneurysms or dot haemorrhages.	18 months Photoscreen.	Primary grader
R2 Mild	>4 Microaneurysms and Dot Haemorrhages. Exudates > 2DD from centre of macula. Some blot and larger haemorrhages acceptable. If more than 20 Mas or haemorrhages per photographic field upgrade to R3 Moderate.	12–18 months Photoscreen.	Secondary grader
R3 Moderate	Any features of Mild. Blot or larger haemorrhages. Up to 1 quadrant of venous beading.	Review by an ophthalmologist in 4–6 months recommended.	Secondary grader
R4 Severe	One or more of: • definite IRMA • 2 quadrants or more of venous beading. • or 4 quadrants of blot or larger haemorrhages.	Review by an ophthalmologist in less than 4 weeks recommended.	Secondary grader
R5 Proliferative Diabetic Retinopathy	One or more of: • Neovascularisation • Subhyaloid or Vitreous Haemorrhage • Traction Retinal Detachment or Retinal Gliosis.	'Fast Track' referral to ophthalmologist. Review in less than 1 week recommended.	Secondary grader

- This chart provides only single field classification examples. For photo screening and grading accuracy Minimum Field size is two 45-degree fields. **Macular Field:** centre of optic disc at nasal edge of field extending temporally at least 4DD from temporal disc margin. **Nasal Field:** Centre of optic disc 1DD from temporal edge of field, extending at least 3DD from nasal disc margin. Additional Superior and Inferior Fields may be taken if retinopathy is suspected. **Image Clarity:** Essential – small blood vessels visible.
- Recommendations for re-screening and referral are based on the grade in worst eye. Grades for peripheral retinopathy and for macular disease for both eyes should be recorded.
- Chart images R3 and M2 are the same which illustrates that the macular field is used in the grading of peripheral retinopathy, and of macular disease.
- For laser-treated retinopathy the grades are RT and/or MT. If retinopathy persists grade and refer as above or, if no, retinopathy undertake biennial screening.
- Non-DHB contracted providers undertaking screening are advised to refer all patients with retinopathy to a public ophthalmology service or a private ophthalmologist. They should also seek advice from their local DHB-designated Retinal Screening Ophthalmologist should they have queries regarding any matter pertaining to screening. For full Retinal Screening Guidelines see Ministry of Health's website: www.moh.govt.nz



↑ Nasal field
Macular field ↓

